

## STUDIES OF EFFICIENCY OF THE COMPOSITE SYSTEM “LYMPHOSILICA” IN MODELING EXPERIMENTAL OBESITY IN RATS

G. V. Ostrovska<sup>1</sup>  
T. V. Krupska<sup>2</sup>  
L. M. Pazyuk<sup>1</sup>  
M. E. Dzerzhynsky<sup>1</sup>  
V. V. Turov<sup>2</sup>

<sup>1</sup>ESC “Institute of Biology and Medicine”  
of Taras Shevchenko National University of Kyiv, Ukraine

<sup>2</sup>Chuiko Institute of Surface Chemistry  
of the National Academy of Sciences of Ukraine, Kyiv

*E-mail: krupska@ukr.net*

Received 28.01.2020

Revised 16.05.2020

Accepted 30.06.2020

The features of the influence of the nanocomposite system (Lymphosilica supplement), which was created on the basis of hydroconsolidated finely divided silica and plant materials with a high content of polyphenols, flavonoids, terpenes, polysaccharides on liver cytophysiological characteristics under the conditions of the development of metabolic syndrome and hepatotoxicity under simulated alimentary, were studied. Biochemical studies of blood serum and histological analysis of liver tissue were performed. It was shown that a high-calorie diet of rats over 100 days leads to the development of individual manifestations of obesity and metabolic syndrome, which are expressed in an increase in body weight and visceral fat, the development of the initial and middle stages of parenchymal fatty liver dystrophy with a decrease in morphological manifestations of the synthetic activity of the nucleus, with slight deviations at the biochemical level. The introduction of a phytocomposite does not lead to pathological changes in the organism of rats, but in some cases leads to manifestations of “adaptive stress” of liver hepatocytes, both with a standard diet and with a high-calorie diet. The positive effect of the composite system on reducing the proportion of visceral fat (by 38%) in rats with a standard diet was shown, and against the background of simulated alimentary obesity, normalization of the level of bilirubin (25 % decrease compared with alimentary obesity) and its fractions, lower levels cholesterol and alkaline phosphatase (in both cases by 19% compared with initial obesity), increased globulin fractions of blood serum, protective effect against dystrophic changes in liver tissue.

**Key words:** nanocomposite, Lymphosilica, nanosilica, rats, alimentary obesity, hepatocytes of the liver, visceralfat.

The efficacy (biological activity) of pharmacological preparations can be enhanced by inclusion in the dosage form the substances that provide a dosed, prolonged release of active substances, their delivery in an intact state to the absorption site and activity sensitizers, which create accelerated mass transfer zones in the absorption sites ensuring increased drugs bioavailability. It was assumed that creation of such systems would reduce the pharmacological burden on a body by increasing the bioactivity and bioavailability of pharmaceuticals and eliminate the possibility of temporary hyperconcentration of toxic substances in various parts of the

body. In particular, the inclusion of drugs in a matrix of biocompatible polymers, such as polyacrylamide, polyurethane, polyvinyl alcohol, etc. would significantly slow down (from several minutes to several days) the process of active substances releasing [1, 2]. However, notwithstanding the polymers used are easily combined with body tissues and do not cause adverse reactions, their elimination is a long multi-stage process. An alternative direction is the use of biodegradable polymers and biopolymers in composites with highly dispersed fumed silica (HDS). At the same time, HDS can perform several functions. It creates a spatially ordered system that

provides optimal conditions for bioactive drugs releasing; serves as a rate controller of substances releasing from the cellulose matrix of medicinal plants; acts as a means of drug delivery to the intestinal mucosa and influences actively on mass transfer in the absorption zone due to the formation of nanostructured layers of aqueous solutions with increased solubility of weakly polar organic compounds (which are related the majority of drugs) [3].

Silica is widely used for biomedical purposes not only as a concomitant substances giving the dosage forms the necessary physico-chemical properties, but also as an independent drug with a pronounced detoxifying effect, well established in the treatment of food poisoning, bacterial and wound infections [4–6]. In recent years, technologies have also been developed for the use of porous silicas as means of targeted drug delivery, involving the creation of nanoscale channels in silica film samples into which a drug can be introduced [7–9]. One of the most important applications of such nanotechnologies is the development of new systems for the controlled release of drugs, with their protection against physiological degradation or elimination [10, 11].

As a medicine for creating a nanocomposite system based on hydrocondensed HDS, the complex highly dispersed plant composite system “Lymphosilica” was used, developed at Chuiko Institute of Surface Chemistry of the National Academy of Sciences of Ukraine [12], containing the components of raw *Echinacea purpurea*, Sudanese rose, dandelion root, enriched with polyphenols, in particular flavonoids (anthocyanins, quercetin), terpenes, polysaccharides.

The effectiveness of the composite system is due to the fact that plant polyphenolic compounds are able to mobilize their own mechanisms of homeostasis in a living organism, stimulate the function of the adrenal cortex, and the secretion of glucocorticoid hormones. Besides, due to HDS presence, it is detoxicant and has a high antioxidant, wound healing, antimicrobial, antifungal, and protistocidal action [13, 14]. Polyphenolic compounds are applied in medical practice for acute and chronic colitis, enteritis, gastritis, inflammatory processes of the oral cavity, ulcers, for detoxification and recovery of the body in chronic diseases. Particularly important is the positive effect of polyphenols on pathogenesis of such conditions as metabolic syndrome, obesity, diabetes, fatty liver. Non-

alcoholic fatty liver disease (NAFLD) is one of the leading causes of chronic liver damage worldwide [15]. Over the past decades, the use of herbal preparations for NAFLD has received increasing attention due to their wide availability, low side effects and proven therapeutic mechanisms [16].

The aim of this work was to study the effects of “Lymphosilica” composite system created on the basis of hydrocondensed silica and plant materials on the manifestations of metabolic syndrome and hepatotoxicity in simulated alimentary obesity in rats.

## Materials and Methods

**Research drugs.** We used finely dispersed silica of the A-300 grade obtained by the Kalush experimental plant of the Chuiko Institute of Surface Chemistry of the National Academy of Sciences of Ukraine. The composition of the phytocomposite “Lymphosilica” includes hydroconsolidated silica (Hidrosil, TU U 20.1-3291669-015:2016) with a bulk density of  $\rho_d = 300 \text{ mg/cm}^3$  and components of micronized plant material — *Hibiscus sabdariffa*, *Taraxacum officinale*, *Calluna vulgaris*, *Calendula officinalis*, *Trifolium pratense*, *Echinacea purpurea*, *Elytrigia repens*. When creating the composite system “Lymphosilica”, silica and phytocomponents were mixed by four-hour processing in a ball mill. The content of the plant component was 30 wt. %.

**Experimental groups of animals.** The rat parameters of seven experimental groups were analyzed in the work ( $n = 8$  in each group) (Table 1). The initial body weight of the animals was  $120 \pm 7 \text{ g}$ . An initial experiment was preliminarily carried out. During 95 days it was modeling alimentary obesity in animals. Herewith the use of highly dispersed silica (HDS) both in pure form and in the said of a nanocomposite system was applied. At the same time, some of the animals were kept on a standard diet, while the rest simulated the development of the metabolic syndrome through the use of high-calorie diets enriched in fats and carbohydrates [17]. The animals received pure HDS, pure phytopreparation (a mixture based on raw materials of *Echinacea*, Sudanese rose, dandelion rhizome, enriched with polyphenolic compounds), or a composite system based on HDS and phytocomposite (“Lymphosilica”) as well. The drugs were administered orally with feed water in the form of an aqueous suspension in a volume of 2 ml per animal (in the morning, 1 hour before a meal).

In all groups of animals, at the end of the period of modeling obesity after instant decapitation, the general morphometric parameters of the body (body weight, growth-weight coefficient (body mass index — Kettle index), and the mass of visceral and subcutaneous fat) were determined. For biochemical and histological analysis, blood serum and organs of the digestive, excretory and endocrine systems, as well as heart and adipose tissue of various types and localizations (white and brown fat, subcutaneous and visceral fat) were selected.

All animal experiments were performed in compliance with the international principles of the European Convention for the Protection of Vertebrate Animals used for Experimental and Other Scientific Purposes (Strasbourg, 1986), Article 26 of the Law of Ukraine “On the Protection of Animals from Cruel Treatment” (No. 3447-IV, 02.21.2006), as well as all the norms of bioethics, biological safety and general ethical principles of animal experiments adopted by the First National Congress of Ukraine on Bioethics (September 2001).

*Biochemical analysis of blood serum.* In the blood serum of all the studied rats, the levels of total bilirubin and its individual fractions were determined [18] as well as total plasma protein, its albumin and globulin fractions [19, 20], glucose [21], cholesterol [22], and the activity of the enzymes alanine and aspartate aminotransferase (ALT and AST, respectively) [23, 24], alkaline phosphatase (ALP) [25]. The level of bilirubin and its fractions was determined using the Biosystems S.A. diagnostic kit. (Spain). The levels of all other indicated serum components and its

enzymatic activity were determined using standard LiquickCor diagnostic kits (Cormay, Poland). Spectrophotometric measurements were performed on a Sinnova BS-3000M biochemical analyzer.

*Histological analysis.* In order to study the effect of nanocomposite systems on the development of histopathological processes in the liver, a macroscopic analysis was done (description of the liver in appearance, anatomical structure, color of the organ, state of the parenchyma and capsules), and histological analysis of this organ. For histological examination, a standard preparation technique was used. To do this, the liver was fixed in 10% formalin, pieces of the organ 1.5×1.5 cm in size were dehydrated, enlightened and soaked in paraffin. The sections of 5–6 µm thick were stained with hematoxylin and eosin to obtain an examination histological specimen.

Subsequently, the obtained histological preparations were analyzed using a light microscope in order to reveal morphological changes in the structure of the histostructure of the lobules of the liver and hepatocytes (the area of hepatocyte nuclei, the state of blood vessels, pathomorphological changes). To do this, micrographs were taken using the System Microscope installation with an Olympus BX 41 system video camera equipped with a Camedia C-5050 zoom digital camera and Olympus DP 80 FT 3.2 software based on a Pentium 4 computer with Windows XP operating system. To evaluate morphometric changes in digital micrographs using the ImageJ program, we measured the area of hepatocyte nuclei (150–250 values per each

Table 1. Experimental groups of animals ( $n = 8$  in each group)

Group designations	Experiment Conditions
1 K	Control, standard food and water regimen
2 A	Standard food regimen + aqueous suspension of HDS (0.3 g/kg body weight, in the morning, 1 hour before meal)
3 F	Standard food regimen + phytopreparation suspension (0.3 g dry matter/kg body weight, in the morning, 1 hour before meal)
4 AF	Standard food regimen + composite system (HDS suspension with phytopreparation, 0.3 g/kg, in the morning, 1 hour before meal)
5 O	High-calorie diet (modeling of obesity, without additional administration of other substances)
6 OF	High-calorie diet + suspension of herbal remedies (0.3 g/kg, in the morning, 1 hour before meal)
7 OAF	High-calorie diet + composite system (0.3 g/kg, in the morning, 1 hour before meal)

series) and calculated the percentage of 1- and 2-nuclear cells and performed statistical analysis using the Student's *t*-test, while the difference was considered probable at  $P < 0.05$ .

## Results and Discussion

*Morphometric parameters of rats in groups with different diets and the use of additives based on silica.*

It was found that differences in the weight of animals in groups with different diets were observed, starting from 75 days of modeling obesity. During this period, a decrease in body weight gain was revealed in animals that received pure HDS, phytopreparation, or a composite system of HDS + phytopreparation (Fig. 1). This primarily concerns animals that were on a standard diet (groups 2A, 3F, 4AF). In animals on a high-calorie diet, a decrease in weight gain with the introduction of a sorbent, herbal preparation or composite system (groups 6 OF, 7 OAF) did not cause significant changes compared with animals that were on the same diet, but without additives.

During the experimental period, no significant difference was found in the growth-weight coefficient (the Kettle body mass index varied in different groups in the range of 6.51–7.34) and in the weight of subcutaneous fat in animals of all groups, except for the group (6 OF), receiving herbal medicine against the background of a high-calorie diet (Fig. 2). At the same time, the weight of visceral fat, which accumulation is one of the manifestations of the metabolic syndrome, was significantly lower in animals treated with both free herbal medicine (by 34%) and a composite system (by

38%) (Fig. 2). However, this decrease applies only to animals that were on a standard diet, while against a background of high-calorie nutrition, the mass of visceral fat not only keep up decrease, but even increases with additional introduction of phytopreparation (Fig. 2), which, obviously, promotes absorption excess carbohydrate and lipid components.

*Biochemical parameters of rat blood serum in groups with different diets and when using additives based on silica.*

Determination of total protein and protein fractions in blood serum gives an idea of the level of protein nutrition and helps to diagnose manifestations of hepatopathy and nephropathy. The concentration of total protein in serum depends mainly on the synthesis and decomposition of two main protein fractions: albumin and globulins.

Our studies showed a significant (11%) increase in total blood protein in groups 2 A (standard diet with HDS) and 7 OAF (composite nanosystem against a high-calorie diet) (Table 2). These changes are due to an increase in the absolute and relative content of globulins, with a constant absolute content of albumin. Such growth is small (6–9%), but significant, both when pure HDS is introduced into the diet of animals in comparison with the control group, and in the groups receiving the studied additives (phytopreparation or composite system) against the background of obesity. An increase in the level of globulins may be due to activation of the synthetic activity of the liver in response to xenogenic substances and enhancement of the immune properties of the blood [22].

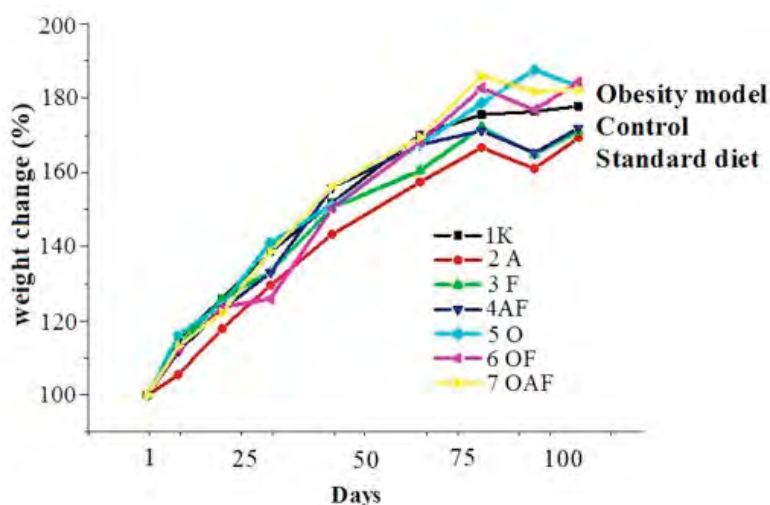


Fig. 1. Change in weight of rats using a standard and high-calorie (O) diet, as well as additional substances -HDS (A), herbal medicine (F), composite system (AF)



Table 2. Indicators of body mass parameters (growth-weight Quetelet index, subcutaneous and visceral fat mass) of rats using standard and high-calorie diets and additional substances

Group	Kettle Index			Subcutaneous fat. g			Visceral fat. g		
	M	$\sigma$	m	M	$\sigma$	m	M	$\sigma$	m
1 K	6.95	0.30	0.12	2.31	0.39	0.16	5.2	0.81	0.33
2 A	6.79	0.56	0.21	2.25	0.55	0.21	4.78	1.95	0.74
3 F	6.68	0.61	0.23	2.23	0.25	0.09	3.43*	0.51	0.19
4AF	6.72	0.91	0.32	2.14	0.23	0.08	3.24*	0.93	0.33
5 O	7.00	0.70	0.26	2.68	0.45	0.17	6.81	1.89	0.71
6 OF	7.34	0.64	0.24	3.17*	0.56	0.21	8.15*	2.12	0.80
7 OAF	6.51	0.66	0.27	2.90	0.91	0.37	7.09	4.44	1.81

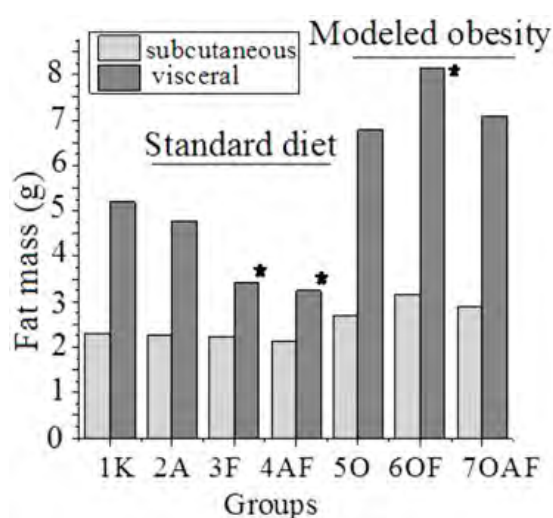


Fig. 2. Weight of visceral fat when using a standard and high-calorie diet and additional substances — silica (2A), polyphenolic herbal medicine (3F), composite system (4AF)

\* —  $P < 0.05$  compared with the control group

When studying the level of bilirubin fractions in blood plasma, an insignificant but reliable increase in its level (from 37% to 70%) was found as with the use of HDS, herbal medicine and composite system in a middle of a standard diet, as with alimentary obesity (Fig. 3, a), although it is well within the physiological norm. At the same time, in case of high-calorie diet using a phytopreparation and nanocomposite system, the level of total and direct bilirubin significantly decreases compared to obese animals that did not receive these additives. The described changes are determined mainly by the indirect bilirubin fraction (Fig. 3, b), the first stage of bilirubin formation from hemoglobin, which is carried out by the cells of

the reticuloendothelial system, most of which are localized in liver (80%, Kupffer cells), as well as in spleen and bone marrow. Preliminarily, an increase in the level of indirect bilirubin can be explained by the “adaptive stress” of liver cells in response to the intake of foreign substances and excess nutrition.

Direct bilirubin (conjugated and soluble form) is formed in hepatocytes to remove bilirubin from the body. Its going down to the control level when it is used affected by obesity, a phytopreparation, and especially a nanocomposite system based on HDS (Fig. 3, c), demonstrates normalization of bile formation by hepatocytes and its outflow through both the intrahepatic and extrahepatic ducts under such conditions.

The hepatoprotective effect of the studied systems is also in evidence when they affect the level of aminotransferases — enzymes that indicate the state of hepatocytes. Under the influence of both a free phytocomplex and the use of a composite system (but not pure HDS), an insignificant (by 15–20%), but reliable decrease in the activity of alanine aminotransferase (ALT) was found in animal groups on both standard and high-calorie diets (Table 3). The level of aspartate aminotransferase (AST) remained unchanged in all groups.

Alkaline phosphatase (ALP) is an enzyme that is extremely common in human and animal tissues, especially in the intestinal mucosa, osteoblasts, and walls of the bile ducts of the liver. It catalyzes the removal of phosphoric acid from its organic compounds with an optimum pH in an alkaline environment (pH 8.6–10.1). The enzyme is contained in the cell membrane and is involved in the transport of phosphorus. The serum alkaline phosphatase activity represents the total activity of its

Table 2. Levels of total protein and protein fractions in rat blood serum using standard and high-calorie diets and additional substances —silica (A), polyphenol herbal medicine (F) and composite system (AF)

Group	Total protein, g/l			Albumen, %			Globulin, %		
	M	$\sigma$	m	M	$\sigma$	m	M	$\sigma$	m
1 K	81.0	7.13	2.52	50.75	1.58	0.56	49.25	1.58	0.56
2 A	90.0*	3.38	1.19	46.25*	2.053	0.73	53.75*	2.05	0.73
3 F	84.75	2.76	0.98	51.75	3.57	1.26	48.25	3.58	1.26
4 AF	82.75	6.86	2.43	51.75	1.39	0.49	48.25	1.39	0.49
5 O	82.0	2.51	0.89	50.25	3.499	1.23	49.75	3.49	1.23
6 OF	80.0	3.62	1.28	47.5*	1.60	0.57	52.5*^	1.60	0.57
7 OAF	89.0*^	2.00	0.71	46.5*^	0.93	0.33	53.5*^	0.93	0.33

Note: \* —  $P < 0.05$  compared with the control group (1K);  
 ^ —  $P < 0.05$  compared with the group with simulated obesity (5O).

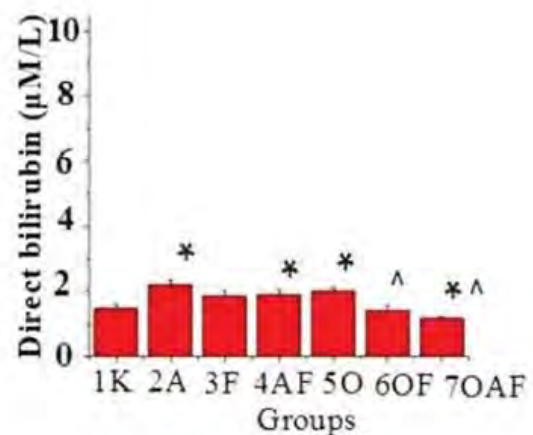
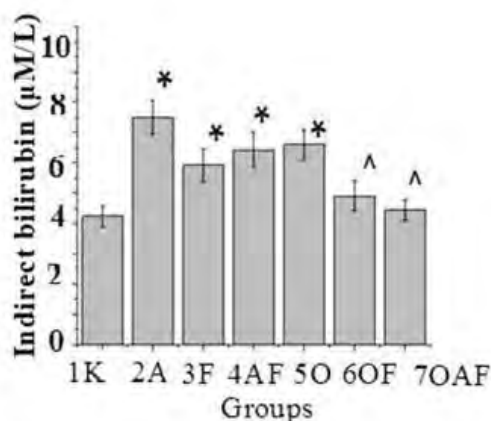



Fig. 3. The levels of bilirubin (a — total; b — indirect; c — direct) in the blood serum of rats using a standard and high-calorie diet, as well as additional substances — HDS (A), herbal medicine (F), composite AF system:

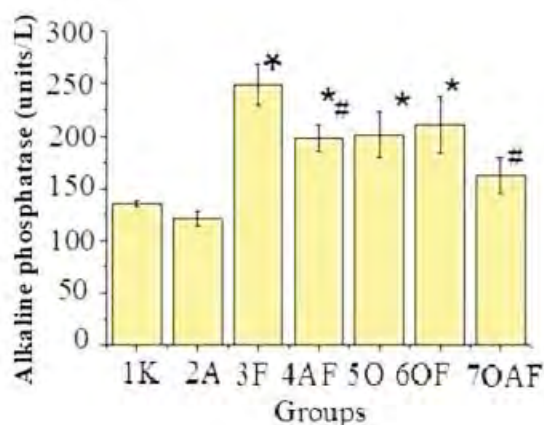
\* —  $P < 0.05$  compared with the control group (1K);  
 ^ —  $P < 0.05$  compared with the group with simulated obesity (5O)

**Table 3. The activity levels of alanine and aspartate aminotransferase in rat blood serum using standard and high-calorie diets and additional substances — HDS (A), herbal medicine (F), composite system (AF)**

Group	AJIT			ACT		
	M	$\sigma$	m	M	$\sigma$	m
1 K	118.75	13.61	4.81	306.50	46.83	16.56
2A	122.00	11.81	4.17	291.25	24.58	8.69
3F	98.25*	5.47	1.93	290.75	31.77	11.23
4AF	96.25*	5.68	2.01	315.50	24.73	8.74
5O	92.00*	10.90	3.85	306.75	61.50	21.74
6OF	64.98*^	5.60	1.98	271.25	47.03	16.63
7OAF	101.57	11.93	4.22	351.00	76.52	27.05

Note: \* —  $P < 0.05$  compared with the control group (1K);

^ —  $P < 0.05$  compared with the group with simulated obesity (5O).



**Fig. 4. Levels of activity of alkaline phosphatase in rat blood serum using a standard and high-calorie diet and additional substances — HDS (A), herbal medicine (F), composite system (AF)**

\* —  $P < 0.05$  compared with the control group (1 K);

# —  $P < 0.05$  compared with the group of the corresponding diet with the addition of a free herbal remedy.

isoenzymes. Hepatic and bone fractions of alkaline phosphatase are always present in the blood serum of adults, and the activity of the hepatic fraction is especially high. Its increase is noted in liver diseases, in particular, bile duct obstruction and inflammation [22, 25].

In our studies, the activity of alkaline phosphatase did not change with daily use of HDS for a month. However, it grew when modeling obesity and especially when using a herbal preparation against the background of such obesity. This can be explained by the

known stimulating effect of the use of various medicinal substances on the functional state of the liver and, in particular, on the activity of alkaline phosphatase [22]. At the same time, the use of phytochemicals as part of a composite system with HDS (both on the standard and high-calorie diets — groups 4 AF and 7 OAF) led to a significant decrease in such activity (Table 5, Fig. 4). Obviously, this is explained by a slower release of phytochemicals from the composite system and, accordingly, a decrease in their stimulating effect (as xenobiotics) on the enzymatic activity of hepatocytes.

Cholesterol is a secondary monoatomic cyclic alcohol that is constantly formed in a body and is used to build cell membranes, synthesize sex and steroid hormones, and vitamin D. Cholesterol enters the body with food, but most of it is synthesized in a liver. The content of cholesterol and triglycerides in blood are the most important indicators of lipid metabolism. There is a direct correlation between an increase in plasma cholesterol concentration and the risk of atherosclerotic coronary artery disease.

Over the period of studies, the level of cholesterol in the blood serum of laboratory animals with a high-calorie diet does not differ from that in animals that were on a standard diet, which is obviously explained by a very short period of modeling the state of obesity, when changes in metabolic processes are at the initial stages of changes. However, an increase in cholesterol level (by 24%, which does not go beyond the physiological norm) was observed in animals receiving pure HDS and a significant

decrease (by 18% in comparison with both the control and the modeled obesity group) in animals receiving a nanocomposite system with a high-calorie diet (Fig. 5). The highest increase in cholesterol in the group treated with pure silica sorbent, according to our assumptions, could be associated with the adsorption capacity of silica and a corresponding decrease in protein fractions of blood plasma, which were also involved in the transportation of cholesterol in the bloodstream. However, such an assumption requires separate experimental evidence.

*Morphological studies of the liver under conditions of application of various diets and additives based on silica and phyto-raw materials.*

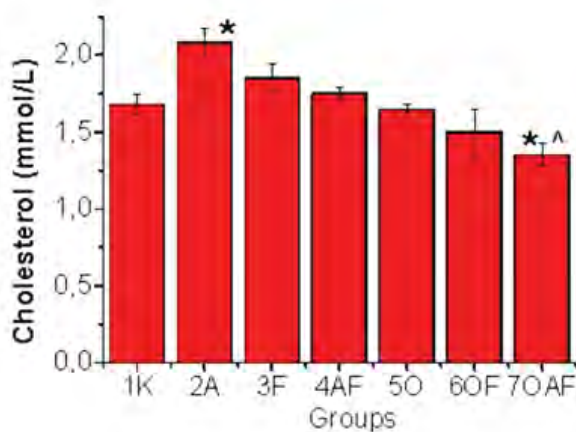
Today, one can consider the association of fatty degeneration of liver with metabolic disorders in a body such as obesity, diabetes mellitus, dyslipidemia, hypertension and a high risk of cardiovascular disorders against the background of this pathology. Moreover, it was shown that not only insulin resistance could lead to fatty hepatitis, but fatty liver disease itself could be the cause of hepatic insulin resistance, especially for type II diabetes, which is registered in more than 370 million people in the world, and the annual increase in patients with this pathology accounts for 5–7% [25, 26]. According to various authors, the prevalence of fatty hepatitis in human's ranges from 6.3% to 33% [28]. Moreover, in patients with various metabolic disorders, such as obesity, diabetes

mellitus, dyslipidemia, the presence of fatty liver disease can reach 75–100%.

Fatty change of liver is microscopically displayed by sharp increase in the content and change in fat composition in hepatocytes. In the liver cells, dusty granules of lipids first appear (the so-called pulverized obesity), then their small drops (so called small-drop obesity), then they merge into large drops (large-drop obesity) or one fatty vacuole that fills the entire cytoplasm and moves the nucleus to the periphery. Modified in this way the liver cells resemble fat. It is proved that more often fat deposition in liver begins on periphery, less often in the center of the lobules. Lipid deposition is diffuse in expressive fatty degeneration of liver cells [27–29].

It is found that in the rats' liver of all groups (both control and experimental), all its macroscopic parts are well defined, the capsule is not strained, the organ surface is smooth, the parenchyma in the section has a uniform red-brown color. Thus, with rat autopsy, no visual deviations from the norm were detected in liver of all the studied groups in comparison with control animals. Based on the analysis of histological preparations, it was found that the liver histostructure in intact animals (control group 1K) has the usual structure, in particular, the structure of the lobule parenchyma and the radial orientation of the hepatic trabeculae are preserved, the interlobular connective tissue layers are moderately expressed. Hepatocytes have a polygonal shape, contain clearly visible nuclei (mainly 1) with 2–3 nucleoli, the cytoplasm is slightly pink (Fig. 6). The severity of anisonucleosis is negligible, the number of binuclear cells is moderate. No disturbances were detected in the microvasculature (Fig. 6).

So, we can conclude about the moderate functional state of the liver of rats in the control group. When intact rats of three series were administrated orally a composite system based on silica, pure silica, plant material (herbal medicine) respectively, the liver histostructure was practically unchanged compared to the control. The trabecular pattern of hepatocytes inside the lobules was preserved, the severity of anisonucleosis was negligible and could be compared with the intact control. On most micropreparations, hepatocytes retained their polygonal shape, homogeneous color of the cytoplasm, and a clear structure of the nuclei. Microcirculatory disorders were not detected. Sinusoidal capillaries did not contain blood, were moderately dilated (Fig. 6). The measurements of the area of hepatocyte nuclei

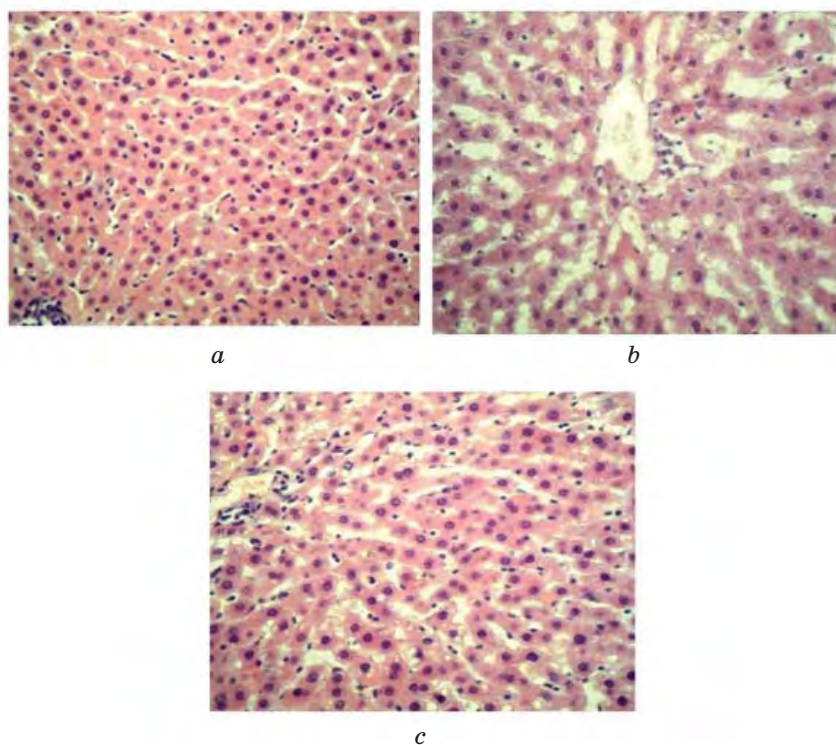


**Fig. 5. The level of cholesterol in the blood plasma of rats using a standard and high-calorie diet and additional substances — HDS (A), herbal medicine (F), composite system (AF):**

\* —  $P < 0.05$  compared with the control group (1K);

^ —  $P < 0.05$  compared with the group with simulated obesity (5O)





**Fig. 6. Micrographs of sections of the liver of rats of the control group (a), with alimentary obesity (group 5 O, b) and with the introduction of a composite system against obesity (group 7 OAF, c) Hematoxylin and eosin staining.  $\times 600$**

in these experimental series did not change (Fig. 7). So, according to the cytoarchitectonics of lobules, trabeculae and the state of hepatocytes, the liver of these animals with the introduction of a composite system, HDS or phytopreparation corresponded to the physiological norm as in the control series of the experiment.

In the animals' liver that were on a carbohydrate and fat-fortified diet (alimentary obesity), significant dystrophic changes in the organ parenchyma were found that corresponded to small and large droplet parenchymal fatty degeneration of hepatocytes. In particular it was the presence of clusters of small drops, sometimes a very large "vacuole" in the cytoplasm of hepatocytes. Hepatocytes in the form of fat cells were appeared. In some places, the normal trabecular structure of particles was significantly disturbed and sinusoidal cavities containing blood cells, mainly red blood cells, expanded dramatically. Anisonucleosis is intensified, and elongated and irregular in shape pyknotic nuclei appeared. At the same time, the synthetic activity of the nuclei decreased compared with the control, since their area was significantly reduced (Fig. 6, 7).

Under conditions of alimentary obesity and introduction of a composite system based

on silica or the initial phytopreparation to rats, an improvement in the morphological and functional state of liver was revealed. It manifested itself in normalization of liver trabecular structure, pronounced narrowing of sinusoidal cavities, which practically did not contain blood. Herewith, the sections of hepatocytes, mainly with dust- and small-droplet obesity, are sometimes found on histological preparations. An analysis of morphometric measurements of the area of hepatocyte nuclei enable to suggest that in the run-up to a composite system or plant material, the functional activity of liver cells increases, since the size of the nuclei increases significantly (Fig. 7). These nuclei are light, rounded, which is consistent with an increase in their transcriptional activity.

Thus, the obtained data indicate an improvement in the histostructure of the organ when using both a composite system and pure silica or free herbal medicine against the background of alimentary obesity, which is probably the result of an increase in compensatory-adaptive reactions of liver tissue.

It has been shown that a high-calorie diet of rats over 100 days leads to the development of individual manifestations of obesity and

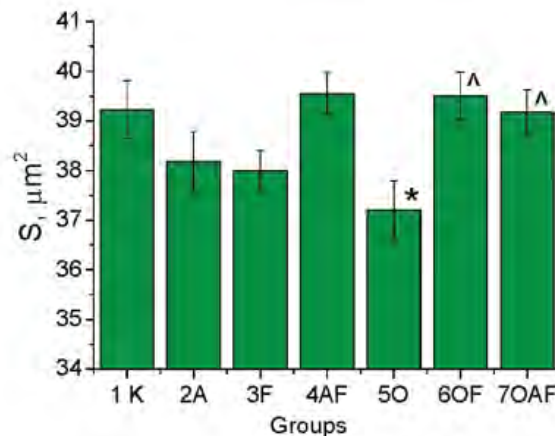


Fig. 7. The size of the area of the nuclei of hepatocytes ( $S, \mu\text{m}^2$ ) in different experimental groups:

\* —  $P < 0.05$  compared with the control group (1K);

^ —  $P < 0.05$  compared with the group of nutritional obesity (5O) without the use of additional drugs

metabolic syndrome, which are expressed in an increase in body weight and a significant increase in visceral fat mass (control — 5.2 g, obesity — 6.81 g).

From the histophysiological characteristics of the liver, the development of the initial and middle stages of parenchymal fatty degeneration (small- and large-droplet obesity of hepatocytes) with morphological manifestations of a decrease in the synthetic activity of the nucleus, pronounced anisonucleosis, and expansion of sinusoidal ducts filled with blood cells were revealed.

With the development of simulated alimentary obesity on liver histological preparations the signs of small- and large-droplet obesity of liver hepatocytes (parenchymal fatty degeneration), the decrease in synthetic activity of hepatocytes, pronounced anisonucleosis, and expansion of sinusoidal cavities with impregnation of blood cells were revealed.

At the biochemical level, deviations from the norm at this stage of the development of obesity are weak and are manifested mainly in a slight increase in the level of total bilirubin ( $8.2 \mu\text{M/l}$  for obesity compared to  $5.8 \mu\text{M/l}$  in the control group) and alkaline phosphatase (K —  $135.325 \text{ u/l}$  and obesity  $200.95 \text{ u/l}$ ).

The additives used are HDS, the composite system “Lymphosilica” or the original phytopreparation do not cause pathological changes in the liver histostructure even with their long-term use.

The phytopreparation injection with a high content of polyphenols, as well as flavonoids, polysaccharide terpenes, leads in some cases to manifestations of “adaptive stress”, in which liver enzymatic activity is activated.

It is shown the positive effect of the composite “Lymphosilica” system based on HDS and herbal remedies on:

- proportion lowering of visceral fat in rats when kept on a standard diet (in the absence of such an effect against the simulated obesity);

- a decrease in the proportion of visceral fat in rats when kept on a standard diet for F (herbal medicine) —  $3.43 \pm 0.19 \text{ g}$  and for AF (Lymphosilica) —  $3.24 \pm 0.33 \text{ g}$  (at a control level of  $5.2 \pm 0.33 \text{ g}$ ), against the background of simulated obesity, this effect was not detected;

- normalization of bilirubin level and its fractions against the simulated obesity (decline from  $8.2 \mu\text{M/l}$  for obesity to  $6.02 \mu\text{M/l}$  (OF) and —  $5.3 \mu\text{M/l}$  (OAF));

- lowering cholesterol (from  $1.65 \pm 0.03 \text{ mM/l}$  for obesity to  $1.35 \pm 0.08 \text{ mM/l}$ ) and alkaline phosphatase (from  $200.95 \pm 22.19 \text{ u/l}$  for obesity, up to  $162.25 \text{ u/l}$ ) under the action of the combined drug Lymphosilica against the background of simulated obesity;

- increased globulin fractions of blood serum (by 8.6% in relation to control).

With the introduction of the composite system “Lymphosilica” or the initial phytopreparation against the background of alimentary obesity, the morphological signs of activation of synthetic processes in the nuclei of hepatocytes are strengthened, which indicates an increase in the compensatory capabilities of hepatocytes and a decrease in the manifestation of parenchymal fatty degeneration, but minor foci of hepatocytes with mainly dust remain.

The publication contains the results of studies conducted with grant support from the State Foundation for Basic Research for the competitive project F76/21.

## REFERENCES

1. Kukolevska O. S., Gerashchenko I. I., Pakhlov E. M. Nanocomposite materials with controlled release of bioactive substances. *Proceedings NaUKMA*. 2016, V. 183. Chemical sciences and technologies. P. 60–64. (In Ukrainian).
2. Karabanova L. V., Gomza Yu. P., Nesin S. D., Bondaruk O. M. Nanocomposites based on multi-component polymer matrices and nanofiller densil for biomedical application. *Nanophysics, Nanophotonics, Surface Studies and Applications*, Chapter 38, Springer. 2016, P. 451–475.
3. Turov V. V., Gerashchenko I. I., Krupskaya T. V., Suvorova L. A. Nanochemistry in solving the problems of endo- and exoecology. *Stavropol: Zebra*. 2017, 315 p. (In Russian).
4. Medical chemistry and clinical application of silica dioxide. Ed. Chuiko A. A. *Kyiv: Nauk. dumka*. 2003, 416 p. (In Russian).
5. Viltsanyuk A. A., Gerashchenko I. I. Enterosorption in the complex treatment of acute surgical diseases of the abdominal organs. *Kharkov*. 2009, 128 p. (In Russian).
6. Enterosorption. Ed. Belyakov N. A. *Leningrad: Center for Sorption Technologies*. 1991, 336 p. (In Russian).
7. Anglin E. J., Cheng L., Freeman W. R., Sailov M. J. Sailor Porous silicon in drug delivery devices and materials. *Adv. Drug Deliv. Rev.* 2008, 60 (11), 1266–1277.
8. Coffer J. L., Whitehead M. A., Nagesha D. K. et al. Porous silicon based scaffolds for tissue engineering and other biomedical applications. *Phys. Status Solidi Appl. Mat.* 2005, 202 (8), 1451–1455.
9. Santos H. A., Mäkilä E., Airaksinen A. J., Hirvonen J. Porous silicon nanoparticles for nanomedicine: preparation and biomedical applications. *Nanomedicine (Lond)*. 2014, 9 (4), 535–554.
10. Liu W., Chaix A., Gary-Bobo M. et al. Stealth Biocompatible Si-Based Nanoparticles for Biomedical Applications. *Nanomaterials (Basel)*. 2017, 7 (10), 288–302. doi: 10.2217/nmm.13.223
11. Rocha-García D., Guerra-Contreras A., Rosales-Mendoza S., Palestino G. Role of porous silicon/hydrogel composites on drug delivery. *Mesoporous Biomater.* 2016, V. 3, P. 93–101.
12. Turov V. V., Krupskaya T. V., Golovan A. P., Andriyko L. S., Kartel M. T. Water binding in composite systems based on milled medicinal plants and nanosilica. *Biotechnol. acta*. 2017, 10 (2), 40–56.
13. Wang S., Moustaid-Moussa N., Chen L. et al. Novel insights of dietary polyphenols and obesity. *J. Nutr. Biochem.* 2014, 25 (1), 1–18.
14. Herranz-López M., Olivares-Vicente M., Encinar J. A., Catalán E., Segura-Carretero A., Joven J., Micol V. Multi-Targeted Molecular Effects of *Hibiscus sabdariffa* Polyphenols: An Opportunity for a Global Approach to Obesity. *Nutrients*. 2017, 9 (8), 907. doi: 10.3390/nu9080907.
15. Katsiki N., Mikhailidis D. P., Mantzoros C. S. Non-alcoholic fatty liver disease and dyslipidemia: An update. *Metabolism*. 2016, 65 (8), 1109–1123.
16. Xiao J., Fai So K., Liang E. C., Tipoe G. L. Recent Advances in the Herbal Treatment of Non-Alcoholic Fatty Liver Disease. *Journal of Traditional and Complementary Medicine*. 2013, 3 (2), 88–94.
17. Shen X. H., Tang Q., Huanet J., Cai W. Vitamin E regulates adipocytokine expression in a rat model of dietary-induced obesity. *Experimental biology and medicine*. 2010, 235 (1), 47–51. doi: 10.1258/ebm.2009.009122
18. Titov V. N., Tvorogova M. G. Methods for the study of bilirubin. *Clinic. lab. diagnostics*. 1994, N 5, P. 36–38. (In Russian).
19. Kotkina T. I., Volkova E. I., Titov V. N. The diagnostic value of a study of serum albumin. *Labor. science*. 1991, N 7, P. 6–12. (In Russian).
20. Titov V. N. Methods for the study of serum albumin. *Clinic. lab. diagnostics*. 1992, N 3–4, P. 3–4. (In Russian).
21. Titov V. N. Methodological aspects of the study of blood glucose. *Clinic. lab. diagnostics*. 1994, N 6, P. 4–8. (In Russian).
22. Clinical diagnosis — laboratory fundamentals. Ed. of Menshikov V. V., with the participation of Dedova I. I., Makolkina V. I., Mukhina N. A. *Moscow: Publishing house "Labinform"*. 1997, 320 p. (In Russian).
23. Biochemical studies in the clinic. *Elista: APP "Dzhangar"*. 1998, 250 p. (In Russian).
24. Titov V. N., Bychkova N. A. Methodological and diagnostic aspects of the study of aminotransferase activity. *Labor. science*. 1990, N 8, P. 412. (In Russian).
25. Tvorogova M. G., Titov V. N. Alkaline phosphatase: research methods and diagnostic value. *Labor. science*. 1991, N 6, P. 1017. (In Russian).
26. Chalasani N., Younossi Z., Lavine J. E., Diehl A. M., Brunt E. M., Cusi K., Charlton M., Sanyal A. J. The diagnosis and management of non-alcoholic fatty liver disease: practice Guideline by the American Association for the Study of Liver Diseases, American College of Gastroenterology, and the American Gastroenterological Association. *Hepatology*. 2012, 55 (6), 2005–2023. doi: 10.1002/hep.25762
27. Rosso N., Chavez-Tapia N. C., Tiribelli C., Bellentani S. Translational approaches: from fatty liver to non-alcoholic steatohepatitis. *World J. Gastroenterol.* 2014, 20 (27), 9038–9049. doi: 10.3748/wjg.v20.i27.9038.
28. Strukov A. I., Surov V. V. Pathological anatomy. *Moscow: GEOTAR-Media*. 2015, 880 p. (In Ukrainian).
29. Blagodarov V. M. Fundamentals of pathomorphology. Chastina 1 Zagalna pathomorphology. *Kyiv: TOV Atlant YuEMSG*. 2007, 198 p. (In Ukrainian).



## БИОМЕТРИЧНІ ДОСЛІДЖЕННЯ ЕФЕКТИВНОСТІ КОМПОЗИТНОЇ СИСТЕМИ «ЛИМФОСИЛІКА» НА ОСНОВІ ЗБОРУ ЛІКАРСЬКИХ РОСЛИН ТА НАНОКРЕМНЕЗЕМУ

Островська Г.В.<sup>1</sup>, Крупська Т.В.<sup>2</sup>,  
Пазюк Л.М.<sup>1</sup>, Дзержинський Н.Е.<sup>1</sup>,  
Туров В.В.<sup>2</sup>

<sup>1</sup>ННЦ «Інститут біології»  
Київського національного університету  
імені Тараса Шевченка, Україна  
<sup>2</sup>Інститут хімії поверхні ім. О.О. Чуйка  
НАН України, Київ

E-mail: krupska@ukr.net

Досліджено вплив нанокompatитної системи на основі високодисперсного кремнезему та рослинної сировини з високим вмістом поліфенолів (добавка «Лімфосиліка») на цитофізіологічні особливості печінки в умовах розвитку метаболічного синдрому при моделюванні аліментарного ожиріння у щурів. Проводилися біохімічні дослідження сироватки крові та гістологічний аналіз тканини печінки. Показано, що висококалорійний раціон щурів протягом 100 днів призводить до розвитку окремих проявів ожиріння і метаболічного синдрому, які виражаються в збільшенні маси тіла і висцерального жиру, розвитку початкових і середніх стадій паренхіматозної жирової дистрофії печінки зі зниженням морфологічних проявів синтетичної активності ядра, з незначними відхиленнями на біохімічному рівні. Введення фітокомпозиту з високим вмістом поліфенолів, а також флавоноїдів, терпенів полісахаридів не зумовлює патологічні зміни в організмі щурів, але в деяких випадках призводить до проявів «адаптаційного напруги» гепатоцитів печінки, як при стандартному раціоні, так і на тлі висококалорійного раціону. Показано позитивний вплив композитної системи на зниження частки висцерального жиру (на 38%) в організмі щурів при стандартному раціоні харчування, а на тлі модельованого аліментарного ожиріння — нормалізація рівня білірубину (зниження на 25% порівняно з аліментарним ожирінням) і його фракцій, зниження рівня холестеролу та лужної фосфатази (в обох випадках на 19% порівняно з початковим ожирінням), підвищення глобулінових фракцій сироватки крові, протективну дію стосовно дистрофічних змін в тканині печінки.

**Ключові слова:** нанокompatит, Лімфосиліка, нанокремнезем, щурі, аліментарне ожиріння, гепатоцити печінки, висцеральний жир.

## БИОМЕТРИЧЕСКИЕ ИССЛЕДОВАНИЯ ЭФФЕКТИВНОСТИ КОМПОЗИТНОЙ СИСТЕМЫ «ЛИМФОСИЛІКА» НА ОСНОВЕ СБОРА ЛЕКАРСТВЕННЫХ РАСТЕНИЙ И НАНОКРЕМНЕЗЕМА

Островская Г.В.<sup>1</sup>, Крупская Т.В.<sup>2</sup>,  
Пазюк Л.М.<sup>1</sup>, Дзержинский Н.Э.<sup>1</sup>,  
Туров В.В.<sup>2</sup>

<sup>1</sup>ННЦ «Институт биологии»  
Киевского национального университета  
имени Тараса Шевченко, Украина  
<sup>2</sup>Институт химии поверхности им. А.А. Чуйко  
НАН Украины, Киев

E-mail: krupska@ukr.net

Исследовано влияние нанокompatитной системы на основе высокодисперсного кремнезема и растительного сырья с высоким содержанием полифенолов (добавка «Лімфосиліка») на цитофизиологические особенности печени в условиях развития метаболіческого синдрома при моделируемом алиментарном ожирении у крыс. Проводились биохимические исследования сыворотки крови и гистологический анализ ткани печени. Показано, что высококалорійный рацион крыс в течение 100 суток ведет к развитию отдельных проявлений ожирения и метаболіческого синдрома, которые выражаются в увеличении массы тела и висцерального жира, развития начальных и средних стадий паренхиматозной жировой дистрофии печени со снижением морфологических проявлений синтетической активности ядра, с незначительными отклонениями на биохимическом уровне. Введение фитокompatита с высоким содержанием полифенолов, а также флавоноидов, терпенов полисахаридов не приводит к патологическим изменениям в организме крыс, но в ряде случаев ведет к проявлениям «адаптационного напряжения» гепатоцитов печени, как при стандартном рационе, так и на фоне высококалорійного рациона. Показано положительное влияние композитной системы на снижение доли висцерального жира (на 38%) в организме крыс при стандартном рационе питания, а на фоне моделированного алиментарного ожирения — нормализация уровня билирубина (снижение на 25% по сравнению с алиментарным ожирением) и его фракций, снижение уровня холестерола и щелочной фосфатазы (в обоих случаях на 19% по сравнению с начальным ожирением), повышение глобулиновых фракций сыворотки крови, протективное действие по отношению к дистрофическим изменениям в ткани печени.

**Ключевые слова:** нанокompatит, Лімфосиліка, нанокремнезем, крысы, алиментарное ожирение, гепатоциты печени, висцеральный жир.